

Cancers of unknown primary site: ESMO Clinical Practice Guidelines for diagnosis, treatment and follow-up[†]

K. Fizazi¹, F. A. Greco², N. Pavlidis³, G. Daugaard⁴, K. Oien⁵ & G. Pentheroudakis³, on behalf of the ESMO Guidelines Committee*

¹Department of Cancer Medicine, Institut Gustave Roussy, University of Paris Sud, Villejuif, France; ²Tennessee Oncology, Centennial Medical Center, Nashville, USA;

³Department of Medical Oncology, University of Ioannina, Ioannina, Greece; ⁴Department of Oncology 5073, Rigshospitalet, Copenhagen University Hospital, Copenhagen, Denmark; ⁵University of Glasgow, Institute of Cancer Sciences, Glasgow, UK

definition, incidence and biology

Cancers of unknown primary site (CUPs) represent a heterogeneous group of metastatic tumours for which a standardised diagnostic work-up fails to identify the site of origin at the time of diagnosis. CUPs account for 3%–5% of all malignancies. The unique biology of these tumours remains almost unknown [1]. Nonetheless, current data suggest that metastatic dissemination can occur in the absence of growth of a primary tumour by virtue of inherent metastatic aggressiveness of cancer cells. Chromosomal instability was recently suggested to account for part of the uncommon clinical presentation, chemoresistance and poor outcome in patients with CUP [2].

diagnosis, pathology and molecular biology

Diagnosis of CUP requires pathology evaluation of a good quality tissue sample. These tumours are categorised by pathology into:

- well- and moderately differentiated adenocarcinomas;
- squamous cell carcinomas;
- carcinomas with neuroendocrine differentiation;
- poorly differentiated carcinomas (including poorly differentiated adenocarcinomas);
- undifferentiated neoplasms.

Immunohistochemistry should be applied meticulously [3, 4] in order to identify the tissue of origin and to exclude chemosensitive and potentially curable tumours (i.e. lymphomas and germ-cell tumours) (Table 1) [III, A]. If the diagnosis is carcinoma or adenocarcinoma, immunostaining for prostate-specific antigen (PSA) in male patients and for oestrogen and

progesterone receptors in females with axillary node metastases is advisable to rule out hormone-sensitive tumours amenable to specific therapy. Staining for keratins CK7 and CK20 may provide indications of a possible primary site, and staining for chromogranin A and synaptophysin is needed to profile neuroendocrine differentiation (Figure 1). Examples of stainings that are rather specific include CK7+, WT-1+, PAX8+, CK20– (ovarian cancer) and RCC+, PAX8+ (renal cancer).

personalised medicine

Several gene expression profiling assays have become commercially available, claiming to blindly and correctly identify a known primary cancer and a likely tissue of origin in patients with CUP in ~80% [6, 7] [III]. These assays are based on mRNA or miRNA RT-PCR or oligonucleotide microarray technologies [8–10]. No significant differences in the tumour microRNA expression profile were evident when CUP metastases biologically assigned to a primary tissue of origin were compared with metastases from typical solid tumours of known origin [11]. These tests may aid in the diagnosis of the putative primary tumour site in some patients [12]. However, their impact on patient outcome via administration of primary site-specific therapy remains questionable and unproven in randomised trials [13] [IV, C]. A large prospective non-randomised phase II study of 252 patients suggested that survival may be improved by site-specific therapy determined by a gene expression profile assay of the biopsy specimen, particularly for patients with a tissue of origin diagnosis of more responsive tumour types [7]. A prospective randomised phase III trial testing such a precision medicine strategy versus empirical chemotherapy is currently on-going in Europe (NCT01540058).

staging and risk assessment

CUPs are by definition metastatic cancers, and the prognosis for patients with CUP is generally poor. However, an appropriate diagnostic work-up can help to identify a minority of CUP patients who can expect to benefit from directed therapy. The following recommendations epitomise the standard and

*Correspondence to: ESMO Guidelines Committee, ESMO Head Office, Via L. Taddei 4, CH-6962 Viganello-Lugano, Switzerland.
E-mail: clinicalguidelines@esmo.org

[†]Approved by the ESMO Guidelines Committee: April 2002, last update July 2015. This publication supersedes the previously published version — Ann Oncol 2011; 22 (Suppl. 6): vi64–vi68.

Table 1. Immunohistochemical work-up in patients with cancers of unknown primary site (CUPs)

	Cytokeratins	PSA	ER, PgR	CDX2+, CK20+, CK7-	TTF1, NapsinA, CK7+	Thyroglobulin, calcitonin	NSE, chromogranin, synaptophysin	AFP, OCT4, hCG, PLAP	LCA	S100, HMB45	Vimentin, desmin
Undifferentiated carcinoma	+	-	±	-	-	-	-	-	-	-	±
Prostate cancer	+	+	-	-	-	-	-	-	-	-	-
Breast cancer	+	-	±	-	-	-	-	-	-	-	±
Colorectal cancer	+	-	-	+	-	-	-	-	-	-	-
Lung adenocarcinoma	+	-	-	-	+	-	-	-	-	-	-
Thyroid cancer	+	-	-	-	±	+	±	-	-	-	-
Neuroendocrine	+	-	-	-	±	±	+	-	-	-	-
Germ-cell cancer	+	-	-	-	-	-	-	+	-	-	±
Lymphoma	-	-	-	-	-	-	-	-	+	-	-
Melanoma	-	-	-	-	-	-	-	-	-	+	±
Sarcoma	-	-	-	-	-	-	-	-	-	±	+

The table shows general staining patterns but exceptions exist, especially for S100 and vimentin. Thyroid and neuroendocrine cancers often positive with CK7 and TTF1 but not with NapsinA. PSA, prostate specific antigen; ER, oestrogen receptor; PgR, progesterone receptor; CK, cytokeratin; TTF1, thyroid transcription factor 1; NSE, neuron-specific enolase; AFP, alpha fetoprotein; hCG, human chorionic gonadotropin; PLAP, placental alkaline phosphatase; LCA, leukocyte common antigen.

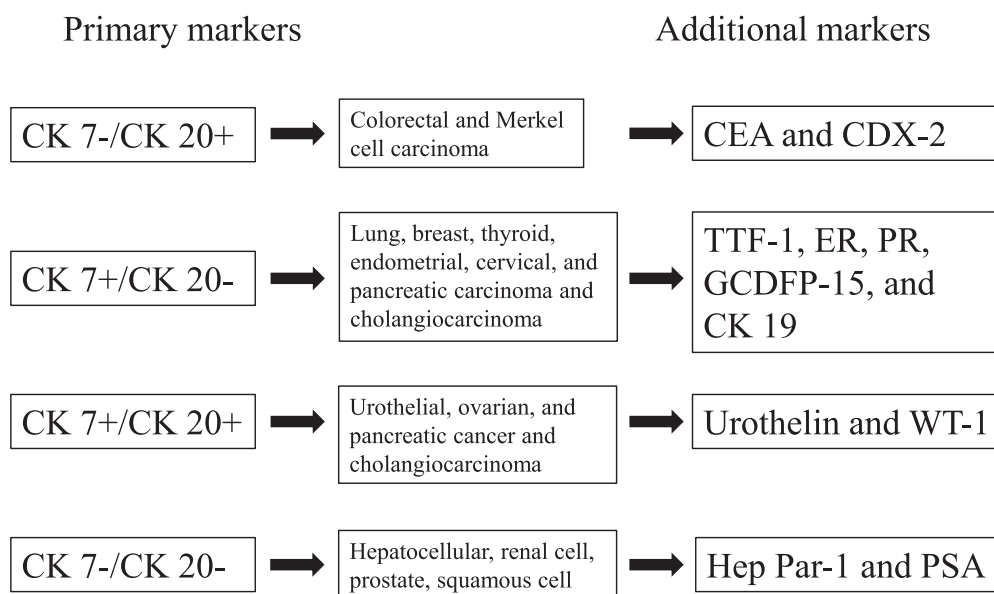


Figure 1. Basic immunohistochemical work-up of cancers of unknown primary. Reproduced with permission: [5]. CK, cyrokeratin; CEA, carcinoembryonic antigen; TTF1, thyroid transcription factor 1; ER, oestrogen receptor; PgR, progesterone receptor; GCDFP-15, gross cystic disease fluid protein-15; WT-1, Wilms tumour gene 1; PSA, prostate specific antigen.

optional assessments suggested. Diagnostic and staging guidelines for patients with an anticipatory CUP diagnosis are summarised in Table 2.

Thorough physical examination (including head and neck, rectal, pelvic and breast examination), basic blood and biochemical analyses, and computed tomography (CT) scans of thorax, abdomen and pelvis constitute a minimal basic work-up [IV, B].

Endoscopies should be sign-, symptom- or laboratory abnormality-guided. Serum assessment of α -fetoprotein, human chorionic gonadotropin, plasma chromogranin A and PSA is suggested in male patients to exclude potentially curable

extragonadal germ-cell tumours, neuroendocrine tumours and prostate cancers amenable to hormonal treatment.

Whole-body 2-deoxy-2-[18F]fluoro-D-glucose-positron emission tomography (FDG-PET)/CT may contribute to the management of patients with cervical adenopathies from CUP and those with a single CUP metastasis [IV, B]. For other CUPs, the role of FDG-PET is limited [14, 15], making this imaging procedure not mandatory in the systematic work-up [III, C].

For patients with predominant midline lymph node involvement, the diagnosis of lymphoma or extragonadal germ-cell tumours should be ruled out.

Table 2. Diagnostic and staging guidelines for cancers of unknown primary site (CUPs)

Assessment suggested	Target patient population
Thorough medical history and physical examination	All patients
Basic blood and biochemistry analyses	All patients
CT scans of thorax, abdomen and pelvis	All patients
Mammography	Female patients
Work-up for CUP subsets	
Breast MRI	Females with axillary adenocarcinoma
Serum α -fetoprotein and human chorionic gonadotropin	Patients with midline metastatic disease
Serum prostate-specific antigen	Males with adenocarcinomatous bone metastases
Head and neck CT/PET scan (optional)	Cervical squamous cell carcinoma
Endoscopies	Sign/symptom/laboratory-oriented
Octreoscan and plasma chromogranin A	Patients with neuroendocrine tumour CUP
Additional diagnostic pathology	Sign/symptom/laboratory-oriented

CT, computed tomography; MRI, magnetic resonance imaging; PET, positron emission tomography.

Distinct subsets of patients with CUP have been defined based on clinical and pathological criteria [2] (Table 3). An additional subset of CUP with a colorectal IHC or molecular profile also seems to have a better prognosis, likely thanks to more active systemic treatments developed over the last two decades for colon cancer [16]. A minority of patients (15%–20%) belong to clinico-pathological subsets with a more favourable prognosis. These favourable-risk CUP patients harbour chemosensitive and potentially curable tumours and may experience long-term disease control with appropriate multidisciplinary management.

The majority of patients (80%–85%) do not belong to specific subsets. Sensitivity to therapy is only modest and median overall survival is generally <1 year (6–10 months). Two prognostic groups can be identified among patients with CUP:

- those with a good performance status (0–1) and a normal lactate dehydrogenase (LDH) value, with a median life expectancy of 1 year, and
- those with either one or both of these prognostic factors (poor performance status and elevated serum LDH), with a median overall survival of only ~4 months [17].

A proposal for the practical management of patients with CUP, including recognition of specific subsets, exclusion of non-CUP neoplasms and the use of prognostic parameters in clinical practice, is summarised in Figure 2.

treatment

Therapy should be individually tailored according to the clinico-pathological subset with a distinct prognosis to which the patient belongs [III, B]. Referral to specialised centres is strongly encouraged. The 10%–15% of CUP patients in the

Table 3. Therapy for patients with favourable-risk cancers of unknown primary site (CUPs)

CUP subtype	Proposed treatment	Potential equivalent tumour
Poorly differentiated neuroendocrine carcinomas of an unknown primary	Platinum + etoposide combination chemotherapy	Poorly differentiated neuroendocrine carcinomas with a known primary
Well-differentiated neuroendocrine tumour of unknown primary	Somatostatin analogues, streptozocin+5-FU, sunitinib, everolimus	Well-differentiated neuroendocrine tumour of a known primary site
Peritoneal adenocarcinomatosis of a serous papillary histological type in females	Optimal surgical debulking followed by platinum-taxane-based chemotherapy	Ovarian cancer
Isolated axillary nodal metastases in females	Axillary nodal dissection, mastectomy or breast irradiation and adjuvant chemohormonotherapy	Breast cancer (found in 50%–70% when breast MRI is performed)
Squamous cell carcinoma involving non-supraclavicular cervical lymph nodes	Neck dissection and/or irradiation of bilateral neck and head-neck axis. For advanced stages induction chemotherapy with platinum-based combination or chemoradiation	Head and neck squamous cell cancer
CUP with a colorectal IHC (CK20+ CDX2+ CK7–) or molecular profile	Systemic treatment used for colorectal cancer	Metastatic colorectal cancer
Single metastatic deposit from unknown primary	Resection and/or RT \pm systemic therapy	Single metastasis
Men with blastic bone metastases or IHC/serum PSA expression	Androgen deprivation therapy \pm RT	Prostate cancer

5-FU, 5-fluorouracil; MRI, magnetic resonance imaging; IHC, immunohistochemistry; PSA, prostate-specific antigen; RT, radiotherapy; CK, cytokeratin.

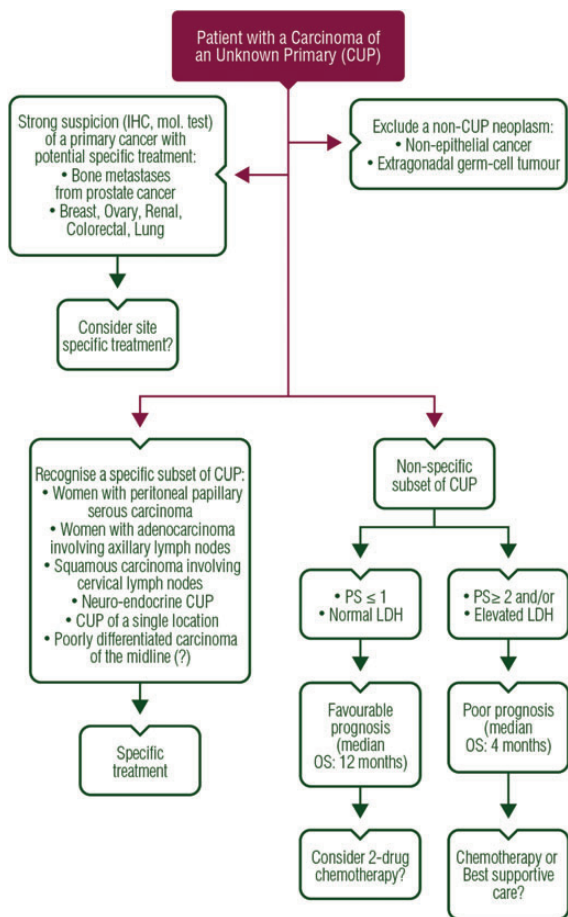


Figure 2. Clinical management of patients presenting with CUPs. IHC, immunohistochemistry; PS, performance status; LDH, lactate dehydrogenase; OS, overall survival.

favourable-risk subsets should be treated similarly to patients with equivalent known primary tumours with metastatic dissemination [IV, B]. These patients achieve long-term disease control in 30%–60% of cases, and optimal management is pivotal for long-term survival (Table 3). Retrospective analyses confirm that the clinical behaviour, biology, response to treatment and outcome of patients with favourable-risk CUP are not different from similar factors relative to metastatic tumours from a known primary site [18–22].

Patients with poor-risk CUP have a dismal prognosis despite management with a variety of chemotherapeutic combinations in small clinical studies [23]. A review conducted in the 2000s showed no evidence of superior efficacy of any of the administered regimens comprising platinum salts, taxanes or new-generation cytotoxic compounds (gemcitabine, vinca alkaloids or irinotecan) [24]. A randomised prospective phase III study of 198 patients compared gemcitabine/irinotecan with paclitaxel/carboplatin/oral etoposide in fit poor-risk patients and reported significantly less toxicity with the two-drug regimen and equal survival rates [II, A] [25]. On the other hand, the efficacy/toxicity ratio of the cisplatin–gemcitabine combination was found to be better than that of the cisplatin–irinotecan regimen in a randomised phase II trial [I, A] [26]. Finally, better outcome was reported with the two-drug cisplatin–gemcitabine regimen when compared with cisplatin alone, although this was not assessed in a large and adequately powered randomised phase III trial [27] (II). Modest survival prolongation and symptom palliation with preservation of quality of life are currently the only realistic aims of therapy for these patients [II, A], although rare cases of cure have been reported [28]. Consequently, low-toxicity patient-convenient chemotherapy regimens should be administered to reasonably fit poor-risk CUP patients (Table 4). If evaluation of patient demographics, metastatic pattern, results

Table 4. Commonly used low-toxicity palliative chemotherapy regimens for poor-risk patients with cancers of unknown primary site (CUPs)

Chemotherapy (mg/m ²)	Time	Interval	Comments
Cisplatin 60–75 + Gemcitabine 1000	Day 1 Day 1+8	Q3 weeks	Fit patients, adequate hydration
Cisplatin 75 + Etoposide 100	Day 1 Day 1–3	Q3 weeks	Fit patients with neuroendocrine-feature CUP, adequate hydration
Paclitaxel 175 + Carboplatin AUC 5	Day 1	Q3 weeks	Convenient outpatient regimen, monitor neurotoxicity
Docetaxel 75 + Carboplatin AUC 5	Day 1	Q3 weeks	Convenient outpatient regimen, monitor neurotoxicity
Irinotecan 160 + Oxaliplatin 80	Day 1	Q3 weeks	Outpatient regimen, monitor for neurotoxicity and diarrhoea
Oral capecitabine 2000 ± Oxaliplatin 85–130	Days 1–14 Day 1	Q3 weeks	Outpatient regimen, risk for diarrhoea and neurotoxicity
Gemcitabine 1000/irinotecan 100	Day 1+8	Q3 weeks	Convenient outpatient regimen, monitor diarrhoea

AUC, area under the curve.

Table 5. Levels of evidence and grades of recommendation (adapted from the Infectious Diseases Society of America–United States Public Health Service Grading System^a)

Levels of evidence	
I	Evidence from at least one large randomised, controlled trial of good methodological quality (low potential for bias) or meta-analyses of well-conducted randomised trials without heterogeneity
II	Small randomised trials or large randomised trials with a suspicion of bias (lower methodological quality) or meta-analyses of such trials or of trials with demonstrated heterogeneity
III	Prospective cohort studies
IV	Retrospective cohort studies or case–control studies
V	Studies without control group, case reports, experts opinions
Grades of recommendation	
A	Strong evidence for efficacy with a substantial clinical benefit, strongly recommended
B	Strong or moderate evidence for efficacy but with a limited clinical benefit, generally recommended
C	Insufficient evidence for efficacy or benefit does not outweigh the risk or the disadvantages (adverse events, costs, ...), optional
D	Moderate evidence against efficacy or for adverse outcome, generally not recommended
E	Strong evidence against efficacy or for adverse outcome, never recommended

^aBy permission of the Infectious Diseases Society of America [32].

of clinical and laboratory tests, imaging data, pathological evaluations and gene expression is relatively unambiguous, a site-specific treatment may be considered, though prospective evidence that this is better than empirical chemotherapy is lacking so far.

Whether targeted agents should be used or not in patients with CUPs is still unknown [29]. Although only a few non-chemotherapy drugs have been tested in patients with CUP, belinostat was randomly assessed and it did not improve the results of the carboplatin-paclitaxel regimen [30]. Preliminary retrospective data suggest that CUP patients with immunohistochemical and/or molecular profile assay diagnoses of ‘colorectal’ carcinomas have response rates and survival after colorectal site-specific therapies (i.e. FOLFOX or FOLFIRI) that are similar to those of patients with known advanced colorectal carcinomas [16, 31] [IV, B]. These data are from small numbers of patients, and additional prospective validation is necessary to substantiate these preliminary findings.

Participation in clinical trials evaluating combinations of cytotoxic compounds with targeted agents or site-specific therapy in patients with putative primary tumour sites highly suspected from immunohistochemical or microarray studies should be strongly encouraged.

response evaluation

Response evaluation is recommended after two or three chemotherapy cycles by individually adequate tests. Quality-of-life issues

are particularly relevant for patients with poor-risk CUP for whom excessive treatment-related toxicity is not justified [IV, B].

follow-up and long-term implications

There is no evidence that follow-up of asymptomatic patients is needed. Specific examinations as clinically indicated.

methodology

These clinical practice guidelines were developed in accordance with the ESMO standard operating procedures for clinical practice guidelines development. The relevant literature has been selected by the expert authors. Levels of evidence and grades of recommendation have been applied using the system shown in Table 5. Statements without grading were considered justified standard clinical practice by the experts and the ESMO faculty. This manuscript has been subjected to an anonymous peer review process.

acknowledgements

The authors thank Lorna Saint Ange for editing the manuscript.

conflict of interest

The authors have declared no conflicts of interest.

references

- Massard C, Loriot Y, Fizazi K. Carcinomas of an unknown primary origin—diagnosis and treatment. *Nat Rev Clin Oncol* 2011; 8: 701–710.
- Vikeså J, Møller AK, Kaczowski B et al. Cancers of unknown primary origin (CUP) are characterized by chromosomal instability (CIN) compared to metastasis of known origin. *BMC Cancer* 2015; 15: 151.
- Oien KA. Pathologic evaluation of unknown primary cancer. *Semin Oncol* 2009; 36: 8–37.
- Abbruzzese JL, Abbruzzese MC, Lenzi R et al. Analysis of a diagnostic strategy for patients with suspected tumors of unknown origin. *J Clin Oncol* 1995; 13: 2094–2103.
- Varadhachary GR. Carcinoma of unknown primary origin. *Gastrointest Cancer Res* 2007; 1: 229–235.
- Greco FA, Lenington WJ, Spigel DR, Hainsworth JD. Molecular profiling diagnosis in unknown primary cancer: accuracy and ability to complement standard pathology. *J Natl Cancer Inst* 2013; 105: 782–790.
- Hainsworth JD, Rubin MS, Spigel DR et al. Molecular gene expression profiling to predict the tissue of origin and direct site-specific therapy in patients with carcinoma of unknown primary site: a prospective trial of the Sarah Cannon Research Institute. *J Clin Oncol* 2013; 31: 217–223.
- Pillai R, Deeter R, Rigl CT et al. Validation and reproducibility of a microarray-based gene expression test for tumor identification in formalin-fixed, paraffin-embedded specimens. *J Mol Diagn* 2011; 13: 48–56.
- Kerr SE, Schnabel CA, Sullivan PS et al. Multisite validation study to determine performance characteristics of a 92-gene molecular cancer classifier. *Clin Cancer Res* 2012; 18: 3952–3960.
- Meiri E, Mueller WC, Rosenwald S et al. A second-generation microRNA-based assay for diagnosing tumor tissue origin. *Oncologist* 2012; 17: 801–812.
- Pentheroudakis G, Spector Y, Krikelis D et al. Global microRNA profiling in favorable prognosis subgroups of cancer of unknown primary (CUP) demonstrates no significant expression differences with metastases of matched known primary tumors. *Clin Exp Metastasis* 2013; 30: 431–439.
- Gross-Goupil M, Massard C, Lesimple T et al. Identifying the primary site using gene expression profiling in patients with carcinoma of an unknown

- primary (CUP): a feasibility study from the GEFCAPI. *Onkologie* 2012; 35: 54–55.
13. Hainsworth JD, Greco FA. Gene expression profiling in patients with carcinoma of unknown primary site: from translational research to standard of care. *Virchows Arch* 2014; 464: 393–402.
 14. Moller AK, Loft A, Berthelsen AK et al. A prospective comparison of 18F-FDG PET/CT and CT as diagnostic tools to identify the primary tumor site in patients with extracervical carcinoma of unknown primary site. *Oncologist* 2012; 17: 1146–1154.
 15. Seve P, Billotey C, Broussolle C et al. The role of 2-deoxy-2-[F-18]fluoro-d-glucose positron emission tomography in disseminated carcinoma of unknown primary site. *Cancer* 2007; 109: 292–299.
 16. Hainsworth JD, Schnabel CA, Erlander MG et al. A retrospective study of treatment outcomes in patients with carcinoma of unknown primary site and a colorectal cancer molecular profile. *Clin Colorectal Cancer* 2012; 11: 112–118.
 17. Culine S, Kramar A, Saghatchian M et al. Development and validation of a prognostic model to predict the length of survival in patients with carcinomas of an unknown primary site. *J Clin Oncol* 2002; 20: 4679–4683.
 18. Spigel DR, Hainsworth JD, Greco FA. Neuroendocrine carcinoma of unknown primary site. *Semin Oncol* 2009; 36: 52–59.
 19. Pentheroudakis G, Pavlidis N. Serous papillary peritoneal carcinoma: unknown primary tumour, ovarian cancer counterpart or a distinct entity? A systematic review. *Crit Rev Oncol Hematol* 2010; 75: 27–42.
 20. Pentheroudakis G, Lazaridis G, Pavlidis N. Axillary nodal metastases from carcinoma of unknown primary (CUPAx): a systematic review of published evidence. *Breast Cancer Res Treat* 2010; 119: 1–11.
 21. Pavlidis N, Pentheroudakis G, Plataniotis G. Cervical lymph node metastases of squamous cell carcinoma from an unknown primary site: a favourable prognosis subset of patients with CUP. *Clin Transl Oncol* 2009; 11: 340–348.
 22. Hainsworth JD, Fizazi K. Treatment for patients with unknown primary cancer and favorable prognostic factors. *Semin Oncol* 2009; 36: 44–51.
 23. Bugat R, Bataillard A, Lesimple T et al. Summary of the standards, options and recommendations for the management of patients with carcinoma of unknown primary site (2002). *Br J Cancer* 2003; 89(Suppl 1): S59–S66.
 24. Goulinopoulos V, Pentheroudakis G, Salanti G et al. Comparative survival with diverse chemotherapy regimens for cancer of unknown primary site: multiple-treatments meta-analysis. *Cancer Treat Rev* 2009; 35: 570–573.
 25. Hainsworth JD, Spigel DR, Clark BL et al. Paclitaxel/carboplatin/etoposide versus gemcitabine/irinotecan in the first-line treatment of patients with carcinoma of unknown primary site: a randomised phase III Sarah Cannon Research Consortium Trial. *Cancer J* 2010; 16: 70–75.
 26. Culine S, Lortholary A, Voigt JJ et al. Cisplatin in combination with either gemcitabine or irinotecan in carcinomas of unknown primary site: results of a randomised phase II study—Trial for the French Study Group on Carcinomas of Unknown Primary (GEFCAPI 01). *J Clin Oncol* 2003; 21: 3479–3482.
 27. Gross-Goupil M, Fourcade A, Blot E et al. Cisplatin alone or combined with gemcitabine in carcinomas of unknown primary: results of the randomized GEFCAPI 02 trial. *Eur J Cancer* 2012; 48: 721–727.
 28. Levy A, Massard C, Gross-Goupil M, Fizazi K. Carcinomas of an unknown primary site: a curable disease? *Ann Oncol* 2008; 19: 1657–1658.
 29. Massard C, Voigt JJ, Laplanche A et al. Carcinoma of an unknown primary: are EGF receptor, Her-2/neu, and c-Kit tyrosine kinases potential targets for therapy? *Br J Cancer* 2007; 97: 857–861.
 30. Hainsworth JD, Daugaard G, Lesimple T et al. Paclitaxel/carboplatin with or without belinostat as empiric first-line treatment for patients with carcinoma of unknown primary site: a randomized, phase 2 trial. *Cancer* 2015; 121: 1654–1661.
 31. Varadhachary GR, Raber MN, Matamorous A, Abbruzzese JL. Carcinoma of unknown primary with colon-cancer profile-changing paradigm and emerging definitions. *Lancet Oncol* 2008; 9: 596–599.
 32. Dykewicz CA. Summary of the guidelines for preventing opportunistic infections among hematopoietic stem cell transplant recipients. *Clin Infect Dis* 2001; 33: 139–144.