

Biliary cancer: ESMO Clinical Practice Guidelines for diagnosis, treatment and follow-up[†]

J. W. Valle¹, I. Borbath², S. A. Khan³, F. Huguet⁴, T. Gruenberger⁵ & D. Arnold⁶ On behalf of the ESMO Guidelines Committee*

¹Department of Medical Oncology, The Christie NHS Foundation Trust, Institute of Cancer Sciences, University of Manchester, Manchester, UK; ²Department of Gastroenterology, Cliniques Universitaires Saint-Luc, Brussels, Belgium; ³Hepatology and Gastroenterology Section, Department of Medicine, Imperial College, London, UK; ⁴Department of Radiation Oncology, Tenon Hospital, APHP, University Paris VI, Paris, France; ⁵1st Department of Surgery, Rudolfstiftung Hospital, Vienna, Austria; ⁶Instituto CUF de Oncologia (I.C.O.), Lisbon, Portugal

Incidence and epidemiology

Biliary tract cancer (BTC), comprising <1% of all human cancers and ~10%–15% of all primary liver cancers, presents mostly in the seventh decade with a small male predominance (male:female ratio of 1.2–1.5:1.0) [1]. They are subclassified as intrahepatic cholangiocarcinoma (iCCA), originating from the biliary tree within the liver, and extrahepatic cholangiocarcinoma (eCCA), outside the liver parenchyma; the latter is further subdivided into perihilar cholangiocarcinoma (pCCA or Klatskin tumour) and distal cholangiocarcinoma (dCCA) [2], with a frequency of 10%–20% iCCA, 50% pCCA and 30%–40% eCCA.

Cholangiocarcinoma

In Europe, USA and Australasia, the incidence of cholangiocarcinoma (CCA) is low (0.3–3.5/100 000); in parts of the world where liver fluke infection is common (e.g. Thailand, China and Korea), rates are much higher [3]. Northeast Thailand has the highest CCA rate in the world, with an annual incidence of 90/100 000, accounting for >80% of all primary liver cancers [4].

CCA incidence and mortality rates have increased overall in the past few decades in most Western countries; specifically, iCCA rates are rising and eCCA rates falling [5], with the exception of Denmark, Norway and the Czech Republic, where iCCA rates have fallen. CCA rates in Asia overall have remained static. These trends may be explained by:

- 1) improved diagnostic tools and imaging;
- 2) misclassification (particularly of pCCA during serial updates of the International Classification of Disease [6]);
- 3) changing migration patterns in the West [7];

- 4) the increasing burden of chronic liver disease (e.g. viral hepatitis and fatty liver disease as specific risk factors for iCCA [8–10]); and
- 5) the potential role of environmental toxins [11, 12].

Furthermore, increased laparoscopic cholecystectomy rates over the past few decades have significantly reduced the prevalence of gallstone disease, a stronger risk factor for eCCA than iCCA [13].

Gallbladder cancer

The incidence of gallbladder cancer (GBC) in Western Europe and the USA is low (1.6–2.0/100 000); however, it is a significant health problem in Chile, India and Central/Eastern Europe. In the Valdivia region of Chile, GBC incidence reaches 24.3/100 000 in females (and 8.6/100 000 in males) [14]. Gallstones are the strongest risk factor for GBC; other risk factors include porcelain gallbladder, gallbladder polyps, primary sclerosing cholangitis, chronic infection (e.g. salmonella typhi), congenital malformations and obesity.

Diagnosis and pathology/molecular biology

When diagnosing a BTC, it is important to distinguish the subtype (iCCA, pCCA, dCCA or GBC) as every subtype has its own specific characteristics, requiring individual workup. Overall, however, the best diagnostic tool is magnetic resonance imaging (MRI) with magnetic resonance cholangiopancreatography (MRCP), contrast-enhanced and diffusion-weighted imaging [15]. Computed tomography (CT) is generally less useful.

Pathology diagnosis should be obtained before any non-surgical treatment modality (not essential in patients planned for curative surgery where radiological features are characteristic). Endoscopic retrograde cholangiopancreatography (ERCP)-guided biopsies are preferred to biliary brush cytology and should be carried out whenever possible [III, A]. Endoscopic ultrasound (EUS)-guided fine needle aspiration (FNA) is also useful for obtaining microbiopsies [16] [II, C] and may be

*Correspondence to: ESMO Guidelines Committee, ESMO Head Office, Via L. Taddei 4, 6962 Viganello-Lugano, Switzerland.
E-mail: clinicalguidelines@esmo.org

[†]Approved by the ESMO Guidelines Committee: August 2008, last update August 2016. This publication supersedes the previously published version—Ann Oncol 2011; 22 (Suppl 6): vi40–vi44.

considered if ERCP-guided brush cytology or biopsies are negative or inconclusive. Cases of tumour seeding along the FNA needle track have been reported [17]; the exact level of risk is uncertain, though it appears to be low. Decisions to undertake biopsy should be made in a multidisciplinary setting, particularly in patients with potentially resectable tumours. Advances in pathology allow identification of distinct pathological subgroups based on immunohistochemistry, reflected in the updated World Health Organization (WHO) classification [18], highlighting the importance of tissue acquisition.

Serum carbohydrate antigen (CA)19-9 (with cut-off >129 U/ml) has some added value [III, C] [19]. In addition, there is an increasing understanding of different genomic profiles across BTC [20], and although currently these differences do not direct therapy, they may do so in future.

staging and risk assessment

Staging needs to take into account the patient's performance status [using WHO or European Cooperative Oncology Group (ECOG) scores], past medical history/co-morbidities and liver function tests (LFTs). Imaging consists of MRI (for assessment of tumour [T]-stage and bile duct involvement), thorax CT (metastases [M]-stage) and EUS (lymph node [N]-stage). Whenever necessary (e.g. inconclusive MRCP), ERCP or percutaneous transhepatic cholangiography (PTC) should be carried out to improve assessment of T-stage, as this is crucial for surgical decision-making [IV, B]. Contrast CT is effective in defining the relationship between the tumour and the vasculature (portal vein and hepatic artery). The utility of positron emission tomography (PET)-CT is controversial and should only be used on a case-by-case basis.

Staging is carried out according to the TNM 2010 system and is specific for every subtype of BTC (see Table 1) [21]; pCCA may be further subclassified according to the Bismuth–Corlette classification (Table 2).

Risk assessment is different for every CCA subtype. When considering pCCA, patients suffering from primary sclerosing cholangitis (PSC) in the Western world and patients with hepatobiliary flukes or hepatolithiasis in Asian countries are at an increased risk. Guidelines for surveillance of PSC patients are available [23]. Cirrhosis and hepatotropic viruses are risk factors for iCCA, with odds ratios (ORs) of 22.92 [95% confidence interval (CI): 18.24–28.79] for cirrhosis, 4.84 (95% CI: 2.41–9.71) for hepatitis C and 5.10 (95% CI: 2.91–8.95) for hepatitis B, according to a recent meta-analysis [8]. The presence of iCCA should be considered in cirrhotic patients although the development of a hepatocellular carcinoma, for which patients are already undergoing screening, is more likely. Screening for CCA in newly defined at-risk groups (e.g. with obesity and the metabolic syndrome [8]) has not been established.

Patients with premalignant lesions predisposing to GBC warrant surveillance; the risk of malignancy is related to the size of gallbladder polyps (the most prevalent finding), which are often found incidentally. Lesions ≥ 20 mm should be managed as GBC after completion of staging investigations. Ultrasound surveillance is recommended for polyps measuring 6–9 mm (6-monthly for 1 year, then annually for 5 years), with resection only in enlarging polyps (to 10–20 mm in size) [24].

management of local/locoregional disease

The therapeutic strategy varies for each type of BTC depending on its site of origin. A treatment algorithm is shown in Figure 1.

intrahepatic cholangiocarcinoma

iCCAs usually arise within normal background liver parenchyma, and their radiological appearance is, most typically, of a mass-forming arterially enhancing tumour. Radical surgical removal with clear margins is the only potentially curative therapy [III, A]. There are well-known prognostic parameters that should be taken into account when assessing prognosis including the presence of lymph node involvement; this has led to the recommendation of routine lymphadenectomy at the level of the hepato-duodenal ligament during surgery [II, A] [25]. Several other factors including size and number of tumours, grade, the presence of satellite nodules, vascular and/or perineural invasion should be reported by the pathologist to guide decisions regarding adjuvant therapy, although robust evidence for its use is lacking [IV, B].

perihilar cholangiocarcinoma (Klatskin tumour)

Diagnosis of a pCCA and assessment of resectability according to the Bismuth–Corlette classification can only be determined in a considerable number of patients with surgical exploration. It is important that, for patients presenting with jaundice, initial radiological imaging is carried out before an ERCP or PTC is undertaken, as the inserted drains/stents obscure the diagnosis and assessment of the extent of disease [III, A]. The practice of biliary drainage before resection (versus immediate surgery) remains controversial and has to be decided on by the treating team taking into consideration non-tumour related factors, such as performance status and co-morbidities [II, B]. The anatomically longer left hepatic duct before segmental distribution usually implies that an extended right hemi-hepatectomy is necessary for curative intent and may require portal vein embolisation (including the segment IV branches) to induce hypertrophy of the future liver remnant (preservable segments II and III) [IV, A] [26]. Segment I, which drains into the ductal bifurcation, where the cancer lies, has to be removed in any curative procedure. Vascular resections at the hilum are possible but their invasion affects prognosis. Lymphadenectomy should be a standard addition in every CCA surgery.

Liver transplantation in locally unresectable cases has been explored in a multidisciplinary approach including a strategy consisting of neoadjuvant chemoradiotherapy followed by liver transplantation by the Mayo Clinic; however, this has not become the standard of care [III, C]. The ongoing French phase III TRANSPHIL trial compares this strategy with standard surgical resection.

distal cholangiocarcinoma

In contrast to the other forms of CCA, this type requires the removal of the pancreatic head, usually a partial duodeno-pancreatectomy (PDP) with extended bile duct resection up to the hilum. PDP is a standard procedure that includes draining lymph node dissection and reconstruction of the stomach and

Table 1. The AJCC/UICC staging of cholangiocarcinoma and gallbladder cancer [21]

Cholangiocarcinoma						Gallbladder cancer	
Cholangiocarcinoma - intrahepatic		Cholangiocarcinoma - perihilar		Cholangiocarcinoma - distal		Gallbladder cancer	
Primary tumour (T)		Primary tumour (T)		Primary tumour (T)		Primary tumour (T)	
TX	Primary tumour cannot be assessed	TX	Primary tumour cannot be assessed	TX	Primary tumour cannot be assessed	TX	Primary tumour cannot be assessed
T0	No evidence of primary tumour	T0	No evidence of primary tumour	T0	No evidence of primary tumour	T0	No evidence of primary tumour
Tis	Carcinoma <i>in situ</i> (intraductal tumour)	Tis	Carcinoma <i>in situ</i>	Tis	Carcinoma <i>in situ</i>	Tis	Carcinoma <i>in situ</i>
T1	Solitary tumour without vascular invasion	T1	Tumour confined to the bile duct, with extension up to the muscle layer or fibrous tissue	T1	Tumour confined to the bile duct histologically	T1	Tumour invades the lamina propria or muscular layer
T2a	Solitary tumour with vascular invasion	T2a	Tumour invades beyond the wall of the bile duct to the surrounding adipose tissue	T2	Tumour invades beyond the wall of the bile duct	T1a	Tumour invades the lamina propria
T2b	Multiple tumours, with or without vascular invasion	T2b	Tumour invades the adjacent hepatic parenchyma	T3	Tumour invades the gallbladder, pancreas, duodenum or other adjacent organs without involvement of the coeliac axis, or the superior mesenteric artery	T1b	Tumour invades the muscular layer
T3	Tumour perforating the visceral peritoneum or involving the local extrahepatic structures by direct invasion	T3	Tumour invades unilateral branches of the portal vein or the hepatic artery	T4	Tumour involves the coeliac axis, or the superior mesenteric artery	T2	Tumour invades the perimuscular connective tissue; no extension beyond the serosa or into the liver
T4	Tumour with periductal invasion	T4	Tumour invades the main portal vein or its branches bilaterally; or the common hepatic			T3	Tumour perforates the serosa (visceral peritoneum) and/or directly invades the liver

and/or one other adjacent organ or structure, such as the stomach, duodenum, colon, pancreas, omentum or extrahepatic bile ducts

T4
Tumour invades the main portal vein or the hepatic artery or invades two or more extrahepatic organs or structures

artery; or the second-order biliary radicals bilaterally; or unilateral second-order biliary radicals with contralateral portal vein or hepatic artery involvement

Regional lymph nodes (N)		Regional lymph nodes (N)		Regional lymph nodes (N)		Regional lymph nodes (N)	
NX	Regional lymph nodes cannot be assessed	NX	Regional lymph nodes cannot be assessed	NX	Regional lymph nodes cannot be assessed	NX	Regional lymph nodes cannot be assessed
N0	No regional lymph node metastasis	N0	No regional lymph node metastasis	N0	No regional lymph node metastasis	N0	No regional lymph node metastasis
N1	Regional lymph node metastasis present	N1	Regional lymph node metastasis (including nodes along the cystic duct, common bile duct, hepatic artery and portal vein)	N1	Regional lymph node metastasis	N1	Metastases to nodes along the cystic duct, common bile duct, hepatic artery and/or portal vein
		N2	Metastasis to periaortic, pericaval, superior mesenteric artery and/or coeliac artery lymph nodes			N2	Metastases to periaortic, pericaval, superior mesenteric artery and/or coeliac artery lymph nodes
Distant metastasis (M)		Distant metastasis (M)		Distant metastasis (M)		Distant metastasis (M)	
M0	No distant metastasis	M0	No distant metastasis	M0	No distant metastasis	M0	No distant metastasis
M1		M1	Distant metastasis	M1	Distant metastasis	M1	Distant metastasis

Continued

Table 1. Continued

Cholangiocarcinoma		Cholangiocarcinoma - perihilar		Cholangiocarcinoma - distal		Gallbladder cancer	
Cholangiocarcinoma - intrahepatic		Cholangiocarcinoma - perihilar		Cholangiocarcinoma - distal		Gallbladder cancer	
Primary tumour (T)	Distant metastasis present	Primary tumour (T)	Distant metastasis present	Primary tumour (T)	Distant metastasis present	Primary tumour (T)	Distant metastasis present
Stage grouping		Stage grouping		Stage grouping		Stage grouping	
Stage 0	N0	Stage 0	M0	Stage 0	M0	Stage 0	M0
Stage I	N0	Stage I	M0	Stage IA	M0	Stage I	M0
Stage II	N0	Stage II	M0	Stage IB	M0	Stage II	M0
Stage III	N0	Stage III	M0	Stage IIA	M0	Stage III	M0
Stage IVA	N0	Stage IIIA	M0	Stage IIB	M0	Stage IIIA	M0
Any T	N1	Stage IIIB	M0	Stage IIB	M0	Stage IIIB	M0
Any T	Any N	Stage IVA	M0	Stage IIB	M0	Stage IVA	M0
Any T	Any N	Stage IVB	M1	Stage III	M1	Stage IVB	M0
Any T	Any N	Any T	Any N	Stage IV	M1	Any T	M1
Any T	Any N	Any T	Any N	Any T	Any N	Any T	Any N

AJCC, American Joint Committee on Cancer; UICC, Union for International Cancer Control. Edge et al. [20]. Used with the permission of the American Joint Committee on Cancer (AJCC), Chicago, IL, USA. The original source for this material is the AJCC Cancer Staging Handbook, 7th edition (2010) published by Springer Science and Business Media LLC, www.springer.com.

the remaining pancreas in various ways to achieve macroscopic cure. The prognosis of dCCA is better than that of adenocarcinoma of the head of the pancreas [III, A] [27].

gallbladder cancer

GBC has two typical presentations: either (a) incidentally diagnosed in the histological workup of simple cholecystectomies or (b) as a symptomatic right upper quadrant tumour at an advanced stage.

The former requires staging with appropriate imaging (MRI or CT) and detailed histopathological analysis to decide whether further resection is necessary, including T-stage, cystic duct margin, involvement of resected lymph nodes, grade, perineural and/or vascular invasion. Every T-stage above T1a and positivity of any mentioned parameters requires a reoperation where a segment IVb/V liver resection together with a ligamentary lymphadenectomy should be carried out [II, A] [28]. If the gallbladder was not removed with a bag during laparoscopic resection or the gallbladder perforated (an adverse prognostic factor), the port sites should also be resected [IV, A].

If GBC is diagnosed during imaging (for symptomatic patients) or when patients present with jaundice, evaluation of potential resectability is the key factor. Advanced T-stage (including T4 tumours) is not a contraindication for resectability provided they are located in the fundus; these tumours require major liver resection with potential resection of the transverse colon. Achieving a curative resection of an advanced tumour located at the infundibulum is much more difficult, because it requires the resection of the bile duct, the duodenal bulb and, potentially, the pancreatic head together with a major hepatectomy, especially if right-sided vessels (right hepatic artery, right portal vein) are involved [III, A].

The prognosis of a gallbladder cancer, if not diagnosed at a very early stage, is somewhat inferior to all other types of CCA.

adjuvant treatment. The high rates of local and distant recurrence following surgery justify the consideration of an adjuvant treatment. The role of adjuvant chemoradiotherapy in this setting is not well defined because of a lack of data from randomised trials. Indeed, most of the published studies are retrospective, including small numbers of patients with a mix of gallbladder and bile duct tumours. In a recent meta-analysis of published data, adjuvant chemotherapy or chemoradiotherapy appears to be associated with a survival benefit in patients with BTC with lymph node-positive disease or with microscopically involved margins (R1 resection) [29]. However, major limitations (including selection bias, heterogeneity of treatments, stage migration over time and variable data quality) preclude definitive conclusions. Moreover, a differentiation between the two modalities (chemotherapy versus chemoradiotherapy) have not been compared in this setting. When employed, the recommended dose of radiotherapy is 45 Gy in fractions of 1.8 or 2 Gy with concurrent 5-fluorouracil (5-FU) or capecitabine [IV, C]. Recently, two prospective trials have assessed a regimen combining a gemcitabine-based adjuvant chemotherapy followed by chemoradiotherapy with concurrent 5-FU [30, 31].

The results of two phase III studies that have completed accrual and are awaiting maturation of data [BilCap

(observation versus adjuvant capecitabine; UK, NCT00363584) and Prodig-12 (observation versus gemcitabine/oxaliplatin; France, NCT01313377)] are awaited and are likely to define future adjuvant strategies. A further study [ACTICCA-1 (observation versus cisplatin/gemcitabine; Germany, NCT02170090)] is open and recruiting patients.

In the absence of level-1 data, the multidisciplinary team may offer adjuvant therapy (radiotherapy, chemoradiotherapy or chemotherapy alone) to patients on the best available evidence and only after a risk-benefit assessment.

management of advanced and/or metastatic disease

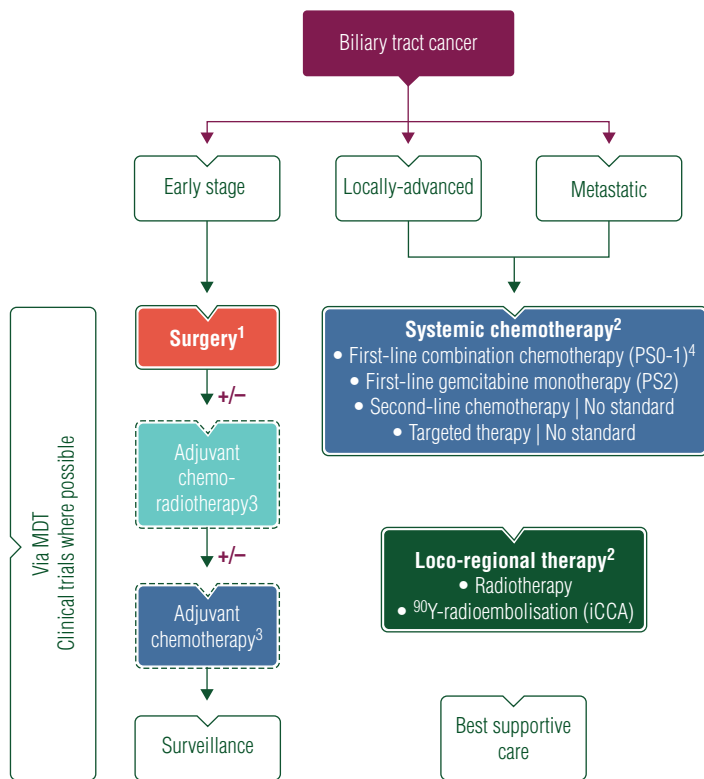
radiation therapy

The role of radiation therapy remains unclear in the treatment of locally advanced but non-metastatic BTC. Chemoradiotherapy has been considered a possible option according to non-randomised studies with median survival rates between 9 and 14 months. The French FFCD 9902 phase III trial compared chemoradiotherapy with chemotherapy alone in this setting [32]. Patients were randomised between chemoradiotherapy (50 Gy with concurrent 5-FU and cisplatin) or chemotherapy with a combination of gemcitabine and oxaliplatin (GemOx). This trial was closed before the completion of

Table 2. The Bismuth–Corlette classification of perihilar cholangiocarcinoma

Type I	Tumour involves the common hepatic duct
Type II	Tumour involves the bifurcation of the common hepatic duct
Type IIIa	Tumour involves the right hepatic duct
Type IIIb	Tumour involves the left hepatic duct
Type IV	Tumour involves both the right and left hepatic ducts

Bismuth *et al.* [22]. Reprinted with permission.



¹ Special considerations:

- Need for pre-operative biliary drainage
- Avoid percutaneous biopsy in resectable disease
- Assess Future Liver Remnant
- Assess need for Portal Vein Embolisation
- Neoadjuvant approach (selected cases)
- Completion surgery for incidental gallbladder cancer of T-stage T1b and above

² Option of salvage surgery should be considered in responding patients with initially inoperable disease

³ Level of recommendation IV,C

⁴ Cisplatin and gemcitabine [category IA], other gemcitabine-based combination [category IIB]

Figure 1. Algorithm for the management of patients with biliary tract cancer. MDT, multidisciplinary team; PS, performance status; iCCA, intrahepatic cholangiocarcinoma.

Table 3. Summary of recommendations

Screening

- Only at-risk populations should be considered for screening, e.g. patients with PSC (screening guidelines in PSC are available)

Diagnosis

- Abdominal ultrasound may be useful for the initial examination (identification of biliary obstruction)
- MRI and MRCP should be carried out before any biliary intervention; CT is less useful
- ERCP allows relief of bile duct obstruction (by stenting); brush cytology and biopsies should be carried out
- For patients deemed suitable for surgery with radical intent, a biopsy is not obligatory (brush cytology may be available). A biopsy should be restricted to selected cases (e.g. equivocal lesion) and only after discussion at a specialist hepatobiliary MDT; if so, EUS-guided biopsy is preferred and percutaneous sampling should be avoided
- For patients with advanced/inoperable disease, histological/cytological confirmation is essential; it may be obtained at EUS or metastatic lesions can be biopsied percutaneously (ultrasound or CT guided)
- FDG-PET imaging has no established role in the diagnosis of BTC
- Baseline CA19-9 should be interpreted with caution and is best used to guide treatment and follow-up; it may have a prognostic value in the absence of biliary obstruction

Staging

- The established staging system for biliary tract cancer is the one developed by the TNM committee of the AJCC/UICC (currently 7th Edition) with subclassifications for GBC and iCCA, pCCA and dCCA
- CT (including thorax and pelvis) allows evaluation of distant metastases and vessel involvement
- MRI plus MRCP is useful for T-staging
- EUS helps to clarify N-stage (\pm nodal biopsy) and adds information regarding vessel involvement
- FDG-PET scan is not routinely recommended for the staging of BTC
- Staging laparoscopy may be considered on an individual basis to exclude the presence of peritoneal metastases if it will influence the decision to proceed with major resection (e.g. locally advanced GBC)
- Pathology examination and reporting of surgically-resected specimens should follow standardised reporting tools (minimum dataset)

Treatment

Curative

- Radical surgery (with lymphadenectomy) is the only curative treatment of BTC; the exact nature and extent of surgery will depend on tumour subtype/ location and should be agreed at a specialist hepatobiliary multidisciplinary tumour board
- Surgery involving hepatic resection will need to take into account the future liver remnant and may require portal vein embolisation
- For patients with incidentally diagnosed GBC (post-cholecystectomy), reoperation with radical intent should be considered for stage T1b and above (\pm resection of port sites)
- Adjuvant therapy (radiotherapy, chemoradiotherapy or chemotherapy alone) may be offered to patients on the understanding that the evidence base is weak and only after risk-benefit assessment; participation in clinical trials should be encouraged
- Neoadjuvant therapy and liver transplant (Mayo Clinic protocol) in early-stage hilar CCA remains investigational; participation in clinical trials should be encouraged
- Patients with initially inoperable, non-metastatic disease should be rediscussed at the multidisciplinary tumour board with a view to salvage surgery in the event of a good response to systemic and/or locoregional treatment, including participation in clinical trials

Palliative

- Systemic chemotherapy is the treatment of choice for patients with locally advanced or inoperable disease; combination chemotherapy for PS 0-1 patients and monotherapy for PS 2 patients
- Cisplatin/gemcitabine is the reference chemotherapy regimen for good PS (0-1) patients; oxaliplatin may be substituted for cisplatin where there is a concern about renal function
- Gemcitabine monotherapy may be considered for PS 2 patients
- There is no established second-line chemotherapy regimen; patients should be encouraged to participate in clinical trials
- There is no established evidence to support the use of targeted therapies; patients should be encouraged to participate in clinical trials
- Radiotherapy may be considered in patients with localised disease, after first-line chemotherapy; patients should be encouraged to participate in clinical trials
- Radioembolisation may be considered in patients with inoperable iCCA, usually after first-line chemotherapy; patients should be encouraged to participate in clinical trials

Best supportive care

- Biliary obstruction is a common occurrence in BTC; establishment of biliary drainage and subsequent stenting should be carried out
- When endoscopic stenting is not possible, percutaneous transhepatic drainage is recommended

Continued

Table 3. *Continued*

- In patients with a life expectancy of >3 months, a metal prosthesis is preferred; some patients require repeat stenting on multiple occasions—anticipation for such an event is required in the planning of stent placement
- Sepsis secondary to biliary obstruction is common and needs to be treated accordingly
- Patients should be advised on the likely duration of stent patency; and of symptoms and signs that are indicative of biliary obstruction or infection and what they need to do in such an event
- Patients should have full access to palliative care and symptom management (including pain control)
- Patients should have a designated point of contact within the multidisciplinary team for advice and support (e.g. nurse specialist)

Follow-up and personalised medicine

- There is no universal 'standard' follow-up schedule; major centres employ a strategy of clinical examination, blood tests (including tumour markers) and CT scan; the intensity of this schedule should be agreed with the patient depending on the stage of disease
- After potentially curative treatment, follow-up should consist of 3-monthly visits during the first 2 years after therapy including clinical examination, laboratory investigation (including LFTs and LDH), tumour markers (CEA or CA19-9 if one/both were known to be elevated before surgery) and CT scan of the thorax, abdomen and pelvis. Visits can be extended to 6-monthly thereafter and prolonged to yearly visits after 5 years of follow-up
- During systemic or locoregional therapy for advanced disease, follow-up should be conducted at a frequency of 8–12 weeks to allow the best assessment of treatment efficacy or as required for disease-related complications. CA19-9 or CEA may be used to monitor the course of the disease if one/both are known to be secreted
- Patients should be encouraged to participate in clinical trials and/or tissue biobanking aimed at defining specific disease subgroups with a view to future risk stratification or selection for specific therapies
- Before participating in clinical trials, patients should have access to all the information required to make an informed decision to give consent, including potential risks and benefits; as well as support for them and their carers in making such decisions

PSC, primary sclerosing cholangitis; CT, computed tomography; MRCP, magnetic resonance cholangiopancreatography; MRI, magnetic resonance imaging; ERCP, endoscopic retrograde cholangiopancreatography; MDT, multidisciplinary team; EUS, endoscopic ultrasound; FDG-PET, fluorodeoxyglucose positron emission tomography; BTC, biliary tract cancer; CA, carbohydrate antigen; TNM, tumour-node metastasis; AJCC, American Joint Committee on Cancer; UICC, Union for International Cancer Control; GBC, gallbladder cancer; iCCA, intrahepatic cholangiocarcinoma; pCCA, perihilar cholangiocarcinoma; dCCA, distal cholangiocarcinoma; CCA, cholangiocarcinoma; PS, performance status; LFTs, liver function tests; LDH, lactate dehydrogenase; CEA, carcinoembryonic antigen.

planned inclusions, after enrolment of 34 patients. There was an advantage for GemOx, both in terms of progression-free survival (median PFS, 11 versus 5.8 months) and overall survival (OS, 20 versus 13.5 months).

Recently, intensity-modulated radiotherapy (IMRT) was shown to allow safe dose escalation [33]. Whether a dose escalation could improve the local control and survival remains unknown.

Experience is growing in the use of radioembolisation using ⁹⁰Y-microspheres for patients with iCCA. Prospective, randomised data are lacking; a pooled analysis of 12 studies including 298 patients showed a median OS of 15.5 months and response rate of 28% [34]. Importantly, 7/73 (10%) patients in three selected studies were converted to resectable disease, highlighting the importance of reassessment of patients in the multidisciplinary team in the event of a good response to any treatment [IV, B].

systemic chemotherapy

Prospective randomised, controlled studies have shown that systemic chemotherapy extends survival in patients with advanced BTC compared with best supportive care [35, 36]. The phase III UK ABC-02 study has established the cisplatin/gemcitabine combination as a standard of care in this disease [I, A], achieving a median survival close to a year (11.7 months) for cisplatin/gemcitabine, compared with 8.1 months for gemcitabine alone (95% CI: 0.53–0.79; $P < 0.001$) [37] with a similar benefit in the randomised phase II Japanese study [38]. A meta-analysis of

these studies has shown that patients benefit from the combination independent of age (<65 versus ≥ 65 years), gender, primary tumour site (intra- versus extrahepatic versus gallbladder versus ampullary), stage of disease (locally advanced versus metastatic) and prior therapy (surgery or stenting); however, patients with performance status 2 may derive the least benefit from the combination [39]. In patients where there is a concern about renal function, oxaliplatin may be substituted for cisplatin [II, B]; in patients with performance status 2, gemcitabine monotherapy may be considered [I, B].

There is no established second-line systemic therapy following progression after first-line treatment although fluoropyrimidine-based therapy (either in monotherapy or in combination with other cytotoxics) is sometimes used [III, C]. A systematic review including 761 patients showed disappointing median PFS (3.2 months; 95% CI: 2.7–3.7) and response rates (7.7%; 95% CI: 4.6–10.9); the mean OS was 7.2 months (95% CI: 6.2–8.2) and no recommendation could be made about the most appropriate second-line regimen [40]. Moreover, the magnitude of benefit to patients (if any) over best supportive care is not known; results of study NCT01926236 (ABC-06) will inform this question.

personalised medicine

The modest gains obtained with systemic chemotherapy highlight the need for improved therapies; the epithelial growth

Table 4. Levels of evidence and grades of recommendation (adapted from the Infectious Diseases Society of America–United States Public Health Service Grading System^a)

Levels of evidence	
I	Evidence from at least one large randomised, controlled trial of good methodological quality (low potential for bias) or meta-analyses of well-conducted randomised trials without heterogeneity
II	Small randomised trials or large randomised trials with a suspicion of bias (lower methodological quality) or meta-analyses of such trials or of trials with demonstrated heterogeneity
III	Prospective cohort studies
IV	Retrospective cohort studies or case–control studies
V	Studies without control group, case reports, experts opinions
Grades of recommendation	
A	Strong evidence for efficacy with a substantial clinical benefit, strongly recommended
B	Strong or moderate evidence for efficacy but with a limited clinical benefit, generally recommended
C	Insufficient evidence for efficacy or benefit does not outweigh the risk or the disadvantages (adverse events, costs, ...), optional
D	Moderate evidence against efficacy or for adverse outcome, generally not recommended
E	Strong evidence against efficacy or for adverse outcome, never recommended

^aBy permission of the Infectious Diseases Society of America [45].

factor receptor (EGFR) and vascular endothelial growth factor (VEGF) axes have been studied the most.

Despite a promising response rate (63%) when adding the EGFR-targeted monoclonal antibody, cetuximab, to gemcitabine and oxaliplatin in a single-arm study (leading to salvage surgery in $n = 9$ [30%] of patients) [41], there was no incremental benefit observed from the addition of cetuximab to GemOx in the randomised phase II BINGO study [42]; similar negative findings were observed with erlotinib or panitumumab with no clear correlation with EGFR overexpression or *k-ras* mutation status.

Prospective randomised phase II studies targeting VEGF have failed to show a benefit of adding sorafenib (an oral multi-tyrosine kinase inhibitor) to single-agent gemcitabine [43] or cediranib (an oral VEGFR-1, -2 and -3, PDGF and c-Kit tyrosine kinase inhibitor) to the cisplatin/gemcitabine combination [44]. There is currently no evidence to support the use of targeted therapies outside the context of a clinical trial.

A better understanding of the molecular pathology of BTC may help identify suitable targets for therapy. Molecular profiling has identified clear differences between CCA and GBC; moreover, intra- and extrahepatic CCAs have different profiles (e.g. IDH-1 and FGFR fusion rearrangements appear in iCCAs only). The significance and clinical relevance (particularly with therapeutic intent) of identifying these signatures are under evaluation.

follow-up and long-term implications

Follow-up after potentially curative treatment should consist of 3-monthly visits during the first 2 years after therapy including

clinical examination, laboratory investigation (including LFTs and lactate dehydrogenase), tumour markers (carcinoembryonic antigen, CA19-9) and CT scan of the thorax, abdomen and pelvis [IV, A]. Regular visits can be extended to 6-monthly thereafter and prolonged to yearly visits after 5 years of follow-up.

In patients receiving treatment of advanced, recurrent or metastatic disease, best supportive care should include active identification and management of obstructive complications. These may include biliary obstruction (requiring biliary drainage and stents, as appropriate); gastric outlet obstruction (requiring duodenal stent or, occasionally, bypass surgery) and/or pancreatic duct obstruction (requiring pancreatic enzyme replacement therapy). Percutaneous transhepatic drainage is recommended if endoscopic stenting is not possible; a metal stent is preferred in patients with a life expectancy of >3 months. Some patients require repeat stenting on multiple occasions; anticipation for such an event is required when planning stent placement. In addition, patients should have full access to palliative care and symptom management (including pain control) throughout their treatment.

methodology

These clinical practice guidelines were developed in accordance with the ESMO standard operating procedures for clinical practice guidelines development, www.esmo.org/Guidelines/ESMO-Guidelines-Methodology. The relevant literature has been selected by the expert authors. A summary of recommendations is shown in Table 3. Levels of evidence and grades of recommendation have been applied using the system shown in Table 4. Statements without grading were considered justified standard clinical practice by the experts and the ESMO faculty. This manuscript has been subjected to an anonymous peer-review process.

conflict of interest

JWV has reported honoraria/consultancy for Lilly, AstraZeneca and Sirtex; research support from Lilly, AstraZeneca and NuCana. SAK has reported speakers' fees for Bayer and BTG. FH has reported research support from Merck Serono and advisory board participation for Merck Serono, MSD and Celgene. TG has reported speakers' bureau member of and research support from Roche, Merck-Serono, Amgen, Sanofi-Aventis and Bayer. DA has reported honoraria/consultancy for Roche, Merck-Serono, Bayer, Lilly and Servier; research support from Roche. IB has declared no potential conflicts of interest.

references

1. Shaib Y, El-Serag HB. The epidemiology of cholangiocarcinoma. *Semin Liver Dis* 2004; 24: 115–125.
2. Nakeeb A, Pitt HA, Sohn TA et al. Cholangiocarcinoma. A spectrum of intrahepatic, perihilar, and distal tumors. *Ann Surg* 1996; 224: 463–473; discussion 473–475.
3. Bragazzi MC, Cardinale V, Carpino G et al. Cholangiocarcinoma: epidemiology and risk factors. *Transl Gastrointest Cancer* 2012; 1: 21–32.
4. Shin HR, Oh JK, Masuyer E et al. Comparison of incidence of intrahepatic and extrahepatic cholangiocarcinoma - focus on East and South-Eastern Asia. *Asian Pac J Cancer Prev* 2010; 11: 1159–1166.

5. Patel T. Worldwide trends in mortality from biliary tract malignancies. *BMC Cancer* 2002; 2: 10.
6. Khan SA, Emadossadaty S, Ladepe NG et al. Rising trends in cholangiocarcinoma: is the ICD classification system misleading us? *J Hepatol* 2012; 56: 848–854.
7. McLean L, Patel T. Racial and ethnic variations in the epidemiology of intrahepatic cholangiocarcinoma in the United States. *Liver Int* 2006; 26: 1047–1053.
8. Palmer WC, Patel T. Are common factors involved in the pathogenesis of primary liver cancers? A meta-analysis of risk factors for intrahepatic cholangiocarcinoma. *J Hepatol* 2012; 57: 69–76.
9. Welzel TM, Graubard BI, El-Serag HB et al. Risk factors for intrahepatic and extrahepatic cholangiocarcinoma in the United States: a population-based case-control study. *Clin Gastroenterol Hepatol* 2007; 5: 1221–1228.
10. Tyson GL, El-Serag HB. Risk factors for cholangiocarcinoma. *Hepatology* 2011; 54: 173–184.
11. Khan SA, Thomas HC, Davidson BR, Taylor-Robinson SD. Cholangiocarcinoma. *Lancet* 2005; 366: 1303–1314.
12. Kumagai S, Kurumatani N, Arimoto A, Ichihara G. Cholangiocarcinoma among offset colour proof-printing workers exposed to 1,2-dichloropropane and/or dichloromethane. *Occup Environ Med* 2013; 70: 508–510.
13. Nordenstedt H, Mattsson F, El-Serag H, Lagergren J. Gallstones and cholecystectomy in relation to risk of intra- and extrahepatic cholangiocarcinoma. *Br J Cancer* 2012; 106: 1011–1015.
14. Bertran E, Heise K, Andia ME, Ferreccio C. Gallbladder cancer: incidence and survival in a high-risk area of Chile. *Int J Cancer* 2010; 127: 2446–2454.
15. Park MJ, Kim YK, Lim S et al. Hilar cholangiocarcinoma: value of adding DW imaging to gadopentetic acid-enhanced MR imaging with MR cholangiopancreatography for preoperative evaluation. *Radiology* 2014; 270: 768–776.
16. Pitman MB, Layfield LJ. Guidelines for pancreaticobiliary cytology from the Papanicolaou Society of Cytopathology: a review. *Cancer Cytopathol* 2014; 122: 399–411.
17. Razumilava N, Gleeson FC, Gores GJ. Awareness of tract seeding with endoscopic ultrasound tissue acquisition in perihilar cholangiocarcinoma. *Am J Gastroenterol* 2015; 110: 200.
18. Bosman FT; World Health Organization; International Agency for Research on Cancer. WHO Classification of Tumours of the Digestive System. Lyon, France: IARC Press 2010.
19. Levy C, Lymp J, Angulo P et al. The value of serum CA 19-9 in predicting cholangiocarcinomas in patients with primary sclerosing cholangitis. *Dig Dis Sci* 2005; 50: 1734.
20. Nakamura H, Arai Y, Totoki Y et al. Genomic spectra of biliary tract cancer. *Nat Genet* 2015; 47: 1003–1010.
21. In Edge SB, Byrd DR, Compton CC et al (eds). *Cancer Staging Handbook from the AJCC Cancer Staging Manual*. New York, NY: Springer 2010; 247–276.
22. Bismuth H, Nakache R, Diamond T. Management strategies in resection for hilar cholangiocarcinoma. *Ann Surg* 1992; 215: 31–38.
23. European Association for the Study of the Liver. EASL clinical practice guidelines: management of cholestatic liver diseases. *J Hepatol* 2009; 51: 237–267.
24. Andrén-Sandberg A. Diagnosis and management of gallbladder polyps. *N Am J Med Sci* 2012; 4: 203–211.
25. de Jong MC, Nathan H, Sotiropoulos GC et al. Intrahepatic cholangiocarcinoma: an international multi-institutional analysis of prognostic factors and lymph node assessment. *J Clin Oncol* 2011; 29: 3140–3145.
26. Matsumoto N, Ebata T, Yokoyama Y et al. Role of anatomical right hepatic trisectionectomy for perihilar cholangiocarcinoma. *Br J Surg* 2014; 101: 261–268.
27. Dickson PV, Behrman SW. Distal cholangiocarcinoma. *Surg Clin North Am* 2014; 94: 325–342.
28. Ito H, Ito K, D'Angelica M et al. Accurate staging for gallbladder cancer: implications for surgical therapy and pathological assessment. *Ann Surg* 2011; 254: 320–325.
29. Horgan AM, Amir E, Walter T, Knox JJ. Adjuvant therapy in the treatment of biliary tract cancer: a systematic review and meta-analysis. *J Clin Oncol* 2012; 30: 1934–1940.
30. Ben-Josef E, Guthrie KA, El-Khoueiry AB et al. SWOG S0809: a phase II Intergroup trial of adjuvant capecitabine and gemcitabine followed by radiotherapy and concurrent capecitabine in extrahepatic cholangiocarcinoma and gallbladder carcinoma. *J Clin Oncol* 2015; 33: 2617–2622.
31. Thet Cho M. Adjuvant gemcitabine plus docetaxel followed by 5FU chemoradiation for patients with resected pancreaticobiliary cancers: a single-institution, phase II study. *J Clin Oncol* 2014; 32 (Suppl.): abstr e22243.
32. Phelip JM, Vendrely V, Rostain F et al. Gemcitabine plus cisplatin versus chemoradiotherapy in locally advanced biliary tract cancer: Fédération Francophone de Cancérologie Digestive 9902 phase II randomised study. *Eur J Cancer* 2014; 50: 2975–2982.
33. Fuller CD, Dang ND, Wang SJ et al. Image-guided intensity-modulated radiotherapy (IG-IMRT) for biliary adenocarcinomas: initial clinical results. *Radiother Oncol* 2009; 92: 249–254.
34. Al-Adra DP, Gill RS, Axford SJ et al. Treatment of unresectable intrahepatic cholangiocarcinoma with yttrium-90 radioembolization: a systematic review and pooled analysis. *Eur J Surg Oncol* 2015; 41: 120–127.
35. Glimelius B, Hoffman K, Sjöden PO et al. Chemotherapy improves survival and quality of life in advanced pancreatic and biliary cancer. *Ann Oncol* 1996; 7: 593–600.
36. Sharma A, Dwary AD, Mohanti BK et al. Best supportive care compared with chemotherapy for unresectable gall bladder cancer: a randomized controlled study. *J Clin Oncol* 2010; 28: 4581–4586.
37. Valle J, Wasan H, Palmer DH et al. Cisplatin plus gemcitabine versus gemcitabine for biliary tract cancer. *N Engl J Med* 2010; 362: 1273–1281.
38. Okusaka T, Nakachi K, Fukutomi A et al. Gemcitabine alone or in combination with cisplatin in patients with biliary tract cancer: a comparative multicentre study in Japan. *Br J Cancer* 2010; 103: 469–474.
39. Valle JW, Furuse J, Jital M et al. Cisplatin and gemcitabine for advanced biliary tract cancer: a meta-analysis of two randomised trials. *Ann Oncol* 2014; 25: 391–398.
40. Lamarca A, Hubner RA, David Ryder W, Valle JW. Second-line chemotherapy in advanced biliary cancer: a systematic review. *Ann Oncol* 2014; 25: 2328–2338.
41. Gruenberger B, Schueller J, Heubrandtner U et al. Cetuximab, gemcitabine, and oxaliplatin in patients with unresectable advanced or metastatic biliary tract cancer: a phase 2 study. *Lancet Oncol* 2010; 11: 1142–1148.
42. Malka D, Cervera P, Foulon S et al. Gemcitabine and oxaliplatin with or without cetuximab in advanced biliary-tract cancer (BINGO): a randomised, open-label, non-comparative phase 2 trial. *Lancet Oncol* 2014; 15: 819–828.
43. Moehler M, Maderer A, Schimanski C et al. Gemcitabine plus sorafenib versus gemcitabine alone in advanced biliary tract cancer: a double-blind placebo-controlled multicentre phase II AIO study with biomarker and serum programme. *Eur J Cancer* 2014; 50: 3125–3135.
44. Valle JW, Wasan H, Lopes A et al. Cediranib or placebo in combination with cisplatin and gemcitabine chemotherapy for patients with advanced biliary tract cancer (ABC-03): a randomised phase 2 trial. *Lancet Oncol* 2015; 16: 967–978.
45. Dykewicz CA. Summary of the guidelines for preventing opportunistic infections among hematopoietic stem cell transplant recipients. *Clin Infect Dis* 2001; 33: 139–144.